



## RESULTS OF LATERAL SURGICAL APPROACHES IN RADICAL RECONSTRUCTIVE OPERATIONS FOR TUBERCULOUS SPONDYLITIS OF THE LUMBAR AND LUMBOSACRAL SPINE

Usmonov I. Kh.

Doctor of Medical Sciences, Head of the Department of Phthiology and Pulmonology Bukhara State Medical Institute,  
uisamiddin @ bk . ru , 90 3250103;

Alimova Gulrukh Salimovna

Assistant of the Department of Phthiology and Pulmonology,  
Bukhara State Medical Institute

### Abstract

The work is based on the survey data of 190 patients with tuberculosis spondylitis (TS) of the lumbar and lumbosacral spine, who underwent surgical intervention using traditional lateral access. In 158 (83.2%) patients, radical reconstructive surgery (RRS) was performed in the lumbar, and in 32 (16.8%) cases - lumbosacral spine. Of these, 127 (66.8%) patients of the affected segment underwent spinal fusion using a titanium mesh cage ( Piramesh ), and 63 (33.2%) using the traditionally classical method with auto bone fusion. The use of traditional lateral access allows the surgeon to fully work in the lumbar spine, but with lesions of the lumbosacral spine, the possibility of detecting VL5, VS1-2 bodies is difficult and dangerous. Damage to muscles, nerves and blood vessels of the abdominal wall, often encountering postoperative complications such as muscle prolapse, abdominal wall hernia, discomfort, and rough scar are considered to be the main disadvantages of lateral access in RVO of the lumbar and lumbosacral spine.

**Keywords:** tuberculosis spondylitis of the lumbar and lumbosacral, surgical treatment, surgical approaches.

### Introduction:

The urgency of this problem is due to the prevalence of infectious lesions of the spine, which range from 2 to 8% of all bone infections. At the same time, the incidence of spondylitis and discitis ranges from 0.5 to 5.9 cases per 100,000 people, and the observation of late diagnosis reaches 75%, and the mortality from spondylitis is 5–12% [1].





The share of extrapulmonary localizations of tuberculosis accounts for 4 to 17%, and the proportion of osteoarticular tuberculosis among extrapulmonary localizations ranges from 5 to 52% [5 ; 12 ]. Tuberculous lesions of the bone structures of the spinal motion segments in the general structure of osteoarticular tuberculosis, according to different authors, range from 45 to 90% [3; 4; 8; 9].

Compression of the spinal cord and its roots occurs in up to 90.7% of patients with TS, signs of neurological disorders - 69% of cases, including spinal disorders - 44%. Despite the implementation of a complex of therapeutic measures, in 60% of cases, patients become disabled [2; 6; 7].

### **Materials and Methods:**

The examination data of 190 patients were analyzed with tuberculous spondylitis of the lumbar and lumbosacral spine, who underwent surgical intervention using traditional lateral access. In 158 ( 83.2 %) patients, a radical reconstructive surgery (RVO) was performed in the lumbar, and in 32 ( 16.8% ) cases - in the lumbosacral spine after appropriate preparation and anti-tuberculosis therapy in terms of an average of up to 1 month. Of these, 127 ( 66.8% ) patients of the affected segment underwent spinal fusion using a titanium mesh cage (Piramesh), and in 63 ( 33.2 %) patients, the traditional-classical method with autologous bone fusion was performed. The age of the patients ranged from 21 to 81 years, with a mean age of 44.7 years. As can be seen from Table 1, there were 1.3 times more men than women, of which 60.5% of patients were aged 19-49 years. Frequent localization of tuberculous lesions of the spine was noted in the lumbar VL 3,4,5 vertebral bodies - in 133 (70.0%) patients. The disease developed slowly - in 96 (50.6%) patients, more than a year; ) patients, in 43 (22.6%) - the clinical course of the disease was acute, with a temperature rise of more than 38.0 0 C , with intoxication, weight loss of more than 10% of the total body weight, with a strong growing pain symptom, dysfunction spinal cord. At the same time, there was a deep destruction of more than 2 bodies of the spine - in 27.9% of patients, instability, epidural, para- and prevertebral abscesses. At the same time, 14 (7.4%) patients were diagnosed with multidrug resistant form of tuberculosis (MDR).

The severity of neurological disorders was assessed before surgery according to the scale of H.L. Frankel (1969) and A.Yu. Mushkin et al. (1998) as follows: degree A and B - not observed; degree C - with incomplete sensory impairment, there are weak movements, but muscle strength is insufficient for walking - 2 (1.0%) patients; grade D - with incomplete sensory impairment below the level of the lesion, there are movements, muscle strength is sufficient for walking with assistance - 39 (20.5%)

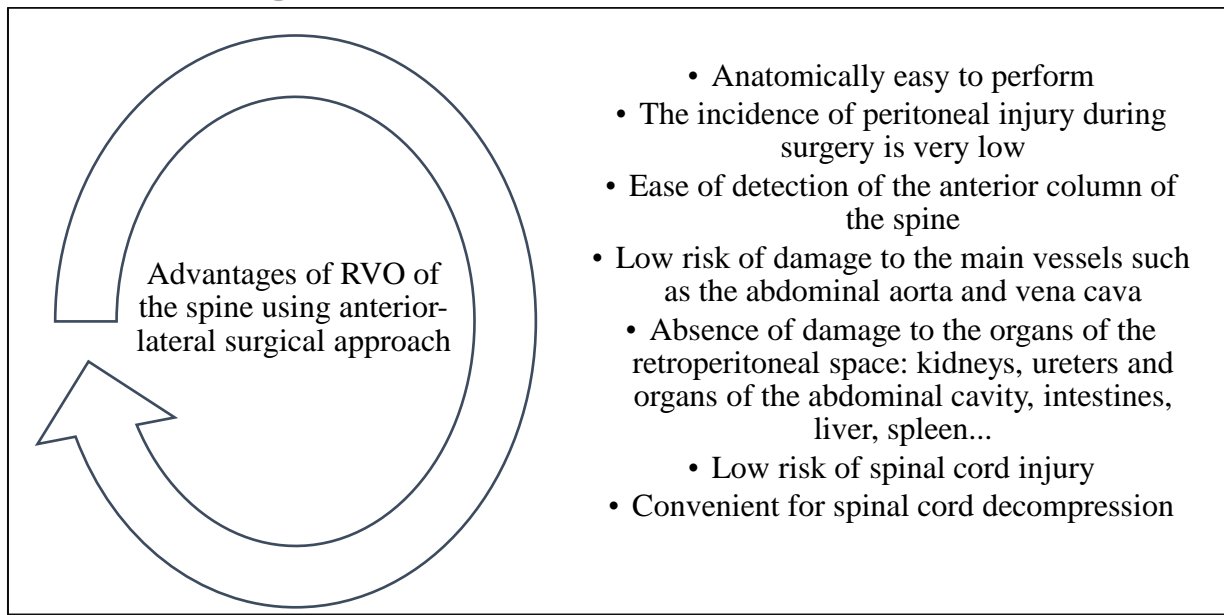




patients; degree E - without violation of sensitivity and movements below the level of the lesion. There may be altered reflexes - in 68 (35.8%) patients; grade R - the presence of radicular syndrome - in 81 (42.7%) patients. The severity of the pain syndrome according to the F.Denis method was 0 points - no; 1 point - 8 (4.2%), 2 points - 24 (12.6%), 3 points - 158 (83.2%), 4 points - no patients, these are those who need to take drugs to relieve pain syndrome.

### **Results and Discussion:**

The effectiveness of operations was studied in the early (up to 30 days) and late postoperative period (from 6 months to 8 years). The results of operations, the advantages and disadvantages of surgical approaches depend on the anatomical features of the operated segment of the spine and the anterolateral abdominal wall. The anterior lateral wall of the abdomen and retroperitoneal space is made up of numerous muscles and fascias, such as the external oblique, internal oblique, transverse abdominal muscle, fascias and passes through the blood supplying the arteries, veins and innervating nerves (a . , v . et n . XII intercostalis ). When using anterolateral surgical approaches to expose the spine, the above muscles , nerves and blood vessels are damaged. The posterolateral wall of the retroperitoneal space is covered with a square muscle of the lower back ( m . quadratus lumborum ), and the sides of the lumbar spine with psoas major and minor ( m . psoas major and minor ), and the lumbosacral spine is surrounded with the lumboiliac muscle ( m . Iliopsoas ) and nerve roots and blood vessels pass inside these muscles. After opening the retroperitoneal space, when the lateral side of the spine is found, the large and small lumbar muscles, sometimes the square muscle, nerve and blood vessels are damaged. The following undesirable complication was observed: prolapse of the muscles of the anterior wall - in 65 (34.2%), postoperative hernia - in 4 (2.1%), rough postoperative scar - in 83 (43.7%), discomfort and impaired sensitivity in the area skin below the surgical incision - in 91 (47.9%) patients, psoitis - in 8 (4.2%), muscle weakness of the lower limb and pain - in 26 (13.7%) patients. It should be noted that, with lesions of the lumbosacral VL 5 and VS 1 department with anterior-lateral access, the detection of the lumbar VL 5 and VS 1 bodies of the spine is quite difficult to do and the anatomy of this area is more dangerous. In many cases, during operations in this area, damage to the iliac veins is observed and it is difficult to detect this segment. In RVO of the lumbar and lumbosacral spine, anterior-lateral surgical approaches have a number of advantages.



**Fig. 1.** Advantages of anterolateral surgical approaches.

The severity of neurological disorders after surgery was according to the scale of H.L. Frankel (1969) and A.Yu. Mushkin et al. (1998) as follows: grade A, B, C and D - not observed; degree E - in 68 (35.8%) patients; grade R - in 27 (14.2%) patients. The severity of the pain syndrome according to the F.Denis method was 0 points - no; 1 point - 18 (9.5%), 2 points - 0, 3 points - 0, 4 points - no patients, these are those who need to take drugs to relieve pain.

## Conclusions

1. Anterolateral RVO approaches for tuberculosis of the lumbar and lumbosacral spine are convenient for detecting the spinal bodies and decompressing the spinal cord.
2. When using anterolateral approaches, the frequency of damage to the peritoneum, great vessels (abdominal aorta and vena cava), retroperitoneal organs (kidneys, ureters), abdominal organs (intestines, liver, spleen, ...) and spinal cord is very low .
3. During surgical treatment of tuberculosis of the lumbar and lumbosacral spine using anterolateral approaches, the following undesirable complication was observed: prolapse of the muscles of the anterior wall - in 65 (34.2%), postoperative hernia - in 4 (2.1%), rough postoperative scar - in 83 (43.7%), discomfort and impaired sensitivity in the area of the skin below the surgical incision - in 91 (47.9%), psoriasis - in 8 (4.2%), muscle weakness of the lower limb and pain - in 26 (13.7%) of patients.



## BIBLIOGRAPHY

1. Isomiddin USMONOV, Umrzok SHUKUROV. (2021). Features of the Clinical Course, the State of Diagnosis and Treatment of Hiv -Associated Pulmonary Tuberculosis in Modern Conditions Literature Review. Annals of the Romanian Society for Cell Biology, 1809–1828. Retrieved from <https://www.annalsofrscb.ro/index.php/journal/article/view/2700>
2. Isomiddin Xaydarovich Usmonov , Nodir Yusufovich Kobilov . (2021). Epidemiology, Clinical Course, Diagnosis and Treatment of Generalized Tuberculosis in Modern Circumstances Literature Review. Annals of the Romanian Society for Cell Biology, 25(2), 3806–3819. Retrieved from <https://www.annalsofrscb.ro/index.php/journal/article/view/1387>
3. Kh UI, Muazzamov BR, Jumaev MF Features of diagnostics and treatment of drug-resistant forms of pulmonary tuberculosis // International journal of pharmaceutical research. - 2021. - T. 13. - No. 1. - S. 2484-2489.
4. Parpiyeva N. N. et al. Features of diagnosis and treatment in generalized forms of tuberculosis // New day in medicine. Bukhara, (2). - 2020. - S. 424-428.
5. Aslonov FI, Rustamova SA, Raxmonova KM Immunopathological aspects in patients with first detected pulmonary tuberculosis // World Bulletin of Public Health. - 2021. - T. 4. - S. 91-95.
6. Ismoilovich AF Tuberculosis Diagnostics with Modern Solutions (Literature Review) //CENTRAL ASIAN JOURNAL OF MEDICAL AND NATURAL SCIENCES. - 2022. - Vol. 3. - No. 3. - S. 377-383.
7. Ismoilovich AF Modern Diagnostic Test for Tuberculosis // European Multidisciplinary Journal of Modern Science. - 2022. - T. 4. - S. 408-412.
8. Aslonov F. EPIDEMIOLOGICAL AND CLINICAL FEATURES OF URINARY TUBERCULOSIS // Eurasian Journal of Medical and natural Sciences . - 2022. - Vol. 2. - No. 10. - S. 59-63.
9. Zhumaev M. F. DIFFICULTIES OF DIAGNOSTICS AND TREATMENT OF DRUG-RESISTANT FORMS OF PULMONARY TUBERCULOSIS // Voprosy nauki i obrazovaniya. – 2021. – no. 15 (140). - S. 21-27.
10. Fatullayevich JM BIOLOGICAL CHARACTERISTICS OF THE CAUSATIVE AGENT OF TUBERCULOSIS IN PATIENTS WITH PULMONARY TUBERCULOSIS // World Bulletin of Public Health. - 2021. - V. 5. - S. 27-32.
11. Alimova G.S. Mass Screening for Tuberculosis Infection in Children Aged 2 to 8 Years // CENTRAL ASIAN JOURNAL OF MEDICAL AND NATURAL SCIENCES. - 2022. - Vol. 3. - No. 3. - S. 368-376.





12. Salimovna AG Diagnosis of Tuberculosis Infection Activity by ELISA and Transcription Analysis Methods //European Multidisciplinary Journal of Modern Science. - 2022. - T. 4. - S. 492 -497.
13. Rakhmonova K.M. Development of Methods for Early Diagnosis, Treatment and Prevention of Chronic Respiratory Failure in Pulmonary Tuberculosis (Literature Review) //CENTRAL ASIAN JOURNAL OF MEDICAL AND NATURAL SCIENCES. - 2022. - Vol. 3. - No. 3. - S. 262-272.
14. Rakhmonova K. M. Tuberculosis Lungs & Related Diseases //CENTRAL ASIAN JOURNAL OF MEDICAL AND NATURAL SCIENCES. - 2021. - Vol. 2. - No. 6. - S. 137-144.
15. Mizrobovna RK Accompanying Diseases of the Respiratory System Pulmonary Tuberculosis // European Multidisciplinary Journal of Modern Science. - 2022. - T. 4. - S. 244 -250.
16. Ulugbek o'gli AM Factors Predicting Mortality in Pulmonary Tuberculosis //CENTRAL ASIAN JOURNAL OF MEDICAL AND NATURAL SCIENCES. - 2022. - Vol. 3. - No. 3. - S. 362-367.
17. Ulugbek o'gli AM Test for Procalcitonin as a Way to Predict Patients with Respiratory Tuberculosis // European Multidisciplinary Journal of Modern Science. - 2022. - T. 4. - S. 486 -491.
18. Rustamova S. A. et al. Study of the causes and factors contributing to the development of relapses of respiratory tuberculosis // Medical Alliance. – 2015. – no. 1. - S. 115-115.
19. Rustamova S. A. et al. The spectrum of drug resistance and the effectiveness of treatment of newly diagnosed patients with pulmonary tuberculosis // Medical Alliance. – 2015. – no. 1. - S. 116-116.
20. Akhtamovna KN Fibrotic Complications in the Lungs in Patients Who Had Had COVID-19 Pathogenesis of COVID-19 // European Journal of Life Safety and Stability (2660-9630). - 2021. - T. 9. - S. 14 -24.
21. Axtamovna KN Optimization of methods of treatment of fibrotic complications in the lungs in patients with tuberculosis and covid-19 //Web of Scientist: International Scientific Research Journal. - 2022. - Vol. 3. - No. 6. - S. 1335-1342.
22. Jumayev M. INFLUENCE OF DIABETES MELLITUS COURSE AND RESULTS OF TUBERCULOSIS TREATMENT //Eurasian Journal of Medical and Natural Sciences. - 2022. - Vol. 2. - No. 10. - S. 52-58.
23. Alimova G. DETECTION OF ADOLESCENT TUBERCULOSIS IN THE REGION OF BUKHARA WITH THE HELP OF THE DRUG"DIASKINTEST" //Eurasian Journal of Medical and Natural Sciences. - 2022. - Vol. 2. - No. 10. - S. 46-51.





24. Rakhmonova K. TUBERCULOSIS AND IRON-CONTAINING CHEMOTHERAPEUTIC DRUGS // Eurasian Journal of Medical and Natural Sciences. - 2022. - Vol. 2. - No. 10. - S. 40-45.
25. Sohibov Z . R ., Akhmadova M . A . Integrated diagnostics And surgical And surgical treatment complicated forms echinococcosis liver ./ OrientalRenaissance:Innovative,Educational , naturalandsocialsciences /2021 th - pp . 203-212.
26. Sohibov Z . R ., Akhmadova M . A . Integrated diagnostics And surgical And surgical treatment complicated forms echinococcosis liver ./ OrientalRenaissance:Innovative,Educational , naturalandsocialsciences /2021 th - pp . 203-212.
27. Ahmadova Maftuna Amine kizi Mammography AND ultrasonic Study IN Diagnostics Local relapse Cancer Dairy Glands .CENTRAL ASIAN JOURNAL OF MEDICAL AND NATURAL SCIENCE./<https://cajmns.centralasianstudies.org/index.php/CAJMNS/article/view/1023>
28. Akhmadova Maftuna Amin Qizi Modern Diagnostics and Surgical Treatment of Complicated Forms of Liver Echinococcosis / CENTRAL ASIAN JOURNAL OF MEDICAL AND NATURAL SCIENCE/<https://cajmns.centralasianstudies.org/index.php/CAJMNS/article/view/1021>
29. Rakhmonova Kamola Muzrobovna. (2022). TUBERCULOSIS AND IRON-CONTAINING CHEMOTHERAPEUTIC DRUGS. EURASIAN JOURNAL OF MEDICAL AND NATURAL SCIENCES, 2(10), 40-45. <https://doi.org/10.5281/zenodo.7123203>.

